

EKG'S MADE EASY

A Primer on how to read EKG's

Ah..the mystery of the EKG. If an EKG is simply a black squiggly line on graph paper, then this short primer is for you! We will give you some tools to understand the EKG better and take the mystery out of it.

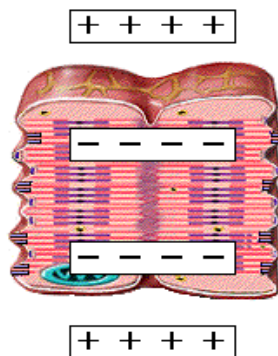
First, what is the EKG anyway? EKG stands for electrocardiogram (yes, it is also known as ECG). It is a tracing of the electrical activity of the heart. It is not a picture of the heart actually pumping, but it is related to its pump activity, as we will see later.

What does the EKG tell us? Well, as we all know, the heart is supposed to beat in a regular fashion. Therefore, its electrical circuit should also repeat in a regular fashion. But sometimes, there's a "short-circuit" of the heart's electrical circuit and it will show up as abnormalities on the EKG.

This primer will show you how the EKG is produced, what the normal EKG looks like and what some of the more common EKG abnormalities look like.

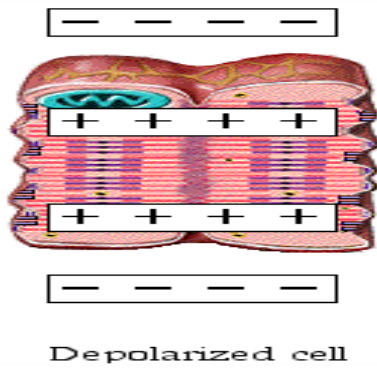
Step 1: How does the heart generate electricity?

Within the heart, certain cells are easily excitable. At rest, these cells have walls or membranes that are *polarized* meaning all the positive charges are outside the membrane and all the negative charges are inside the membrane. [Think of a battery: one end is positive and the other end is negative]



Repolarized cell

When the cell becomes excited, channels open up inside the cell membrane, allowing those positive charges to travel from the outside to the inside. In effect, the charge across the membrane becomes neutralized. This process is called *depolarization*.



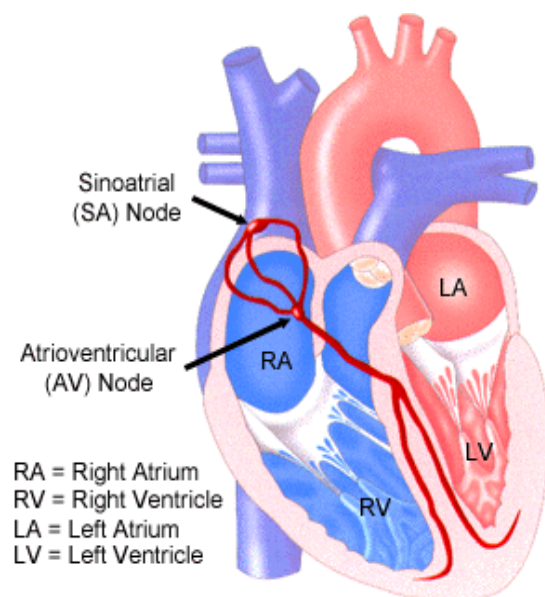
This depolarization process travels like a wave from one cell to another on a specific path through the heart. Think of it as a wave that occurs in a football stadium. One section starts the wave, then the next, and then the next, until the wave travels throughout the entire stadium.

The process of depolarization creates an electrical signal that is captured by the EKG machine. The electrical activity is transferred from the electrodes to the machine which prints it out on paper.

Once the cell has finished depolarizing the positive ions are pushed out of the cell again to *repolarize* the membrane.

Step 2: What is the pathway that this electrical circuit takes?

The electrical circuit travels in a specific pathway through the heart. Think back to our football stadium wave example. Now imagine that the wave only travels through one row, all the way around the stadium. That's how the electrical pathway travels through the heart.



The electrical circuit starts in the right atrium, in the SA node or the *Sino-Atrial Node*. It then travels through the atrium to a spot near the ventricles called the AV node or the *Atrial-Ventricular Node*. It travels next to a spot in the wall in between the right and left ventricles (the intraventricular septum) call the *Bundle of His* (pronounced “hiss” not “his n’ hers”). Then it splits into two and travels down the intraventricular septum to the bottom of the ventricles where it wraps around the bottom and travels up the side of the ventricles. These two branches are called the Purkinjie Fibers (“purr-kin-gee fibers”).

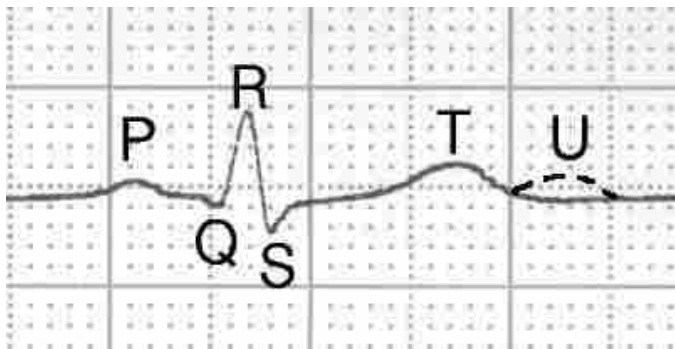
So, in short, the circuit goes from the SA Node to the AV Node to the Bundle of His to the Purkinjie fibers. (repeat this again and again until you have it memorized—this is important!!!)

Step 3: So, how do we relate the EKG graph to the actual beating of the heart?

This circuit stimulates the areas of the heart that it is traveling through and makes the muscle contract. So, not surprisingly, the pathway of the heart contraction roughly follows the sequence of the electrical circuit.

The SA node will fire, and very very quickly thereafter, the atria will contract. The impulse goes down to the AV node, then through the Bundle of His and to the Purkinjie fibers. This prompts contraction of the ventricular muscles. Remember how the Purkinjie fibers wrapped around the base of the ventricles and the excitation traveled up the walls? That is how the ventricles contract: from the bottom up (think of how you are supposed to roll up a toothpaste tube, from the bottom). This is important because the ventricles are supposed to squeeze the blood from the bottom to the Pulmonary artery (right ventricle) and the Aorta (left ventricle).

Step 4: Explain the EKG graph to me:



The different waves of the EKG are labeled. The first wave is the P wave which represents atrial depolarization. This is followed by the Q, R and S waves which are usually lumped all together called the QRS complex. The QRS complex represents ventricular depolarization. The final wave is called the T wave and it represents ventricular repolarization.

So, again to recap:

P wave = atrial depolarization

QRS complex = ventricular depolarization

T wave = ventricular repolarization.

Wait a minute, you say. What happened to atrial repolarization?? It does occur, but you don't see the wave because it gets buried in the QRS complex.

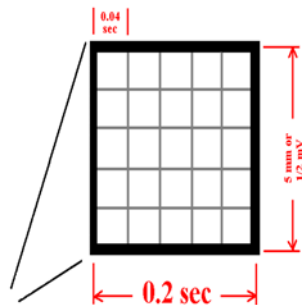
Step 5: What does the EKG tell us?

We can learn a lot of things about the heart from the EKG. It tells us rate, rhythm, and some more complicated things like axis and hypertrophy (don't worry, it is not covered here) and, importantly, if someone is having or had a heart attack.

We will be mostly concerned with rate and rhythm in this primer.

Step 6: Determining Rate

The EKG is printed on graph paper. The size of the graph paper is standardized for all the machines. Some of you may have seen an EKG machine that has a roll of graph paper that rolls out as the stylus prints the tracing. The rate that the paper rolls out is also standard.



Note that there are heavy black lines and then 4 lighter lines in between them. The horizontal axis represents the time aspect while the vertical axis represents the strength of the signal. The time in between the two heavy black lines is .2 sec or in between each little lighter square is .04 seconds.

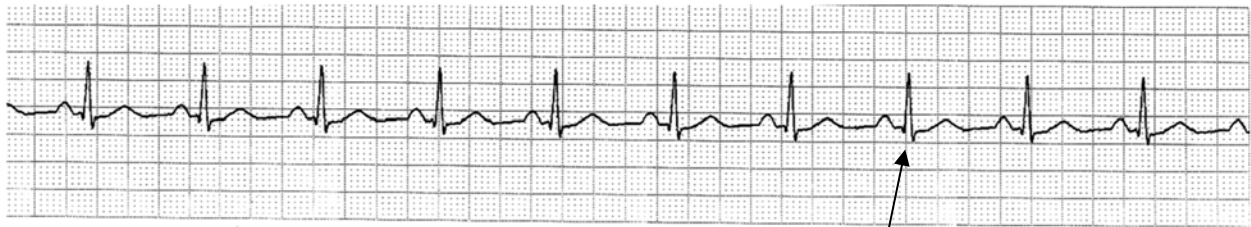Do you remember the names for our rates?

Normal rate = in between 60 and 100 beats per minute

Faster rate = greater than 100 beats per minute = tachycardia

Slower rate = slower than 60 beats per minute = bradycardia

To determine the rate from the EKG, let's look at an actual strip:



First: find an R wave that falls on a heavy black line in the graph:

Second: Now, ignore the EKG tracing. Just concentrate on the graph paper.

Third: count off and label each heavy dark line as follows: 300-150-100-75-60-50

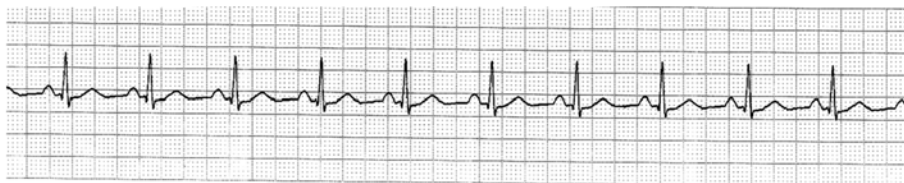Fourth: Now, look at the EKG tracing. Where does the next R wave fall? That is your rate. On our example above, the next wave falls approximately on the 75 line, so this patient's heart is beating around 75 beats per minute.

The heart has automaticity foci within it. Huh? These are areas of the heart that have an "auto-start" feature. So the atria have an intrinsic rate of 60-80 beats per minute. If, for some reason, the atria could not function, the AV junction would kick in at an inherently slower rate of about 40-60 beats per minute. If both of those sites could not function, as a last resort, the ventricles themselves have an inherit rate of 20-40 beats per minute.

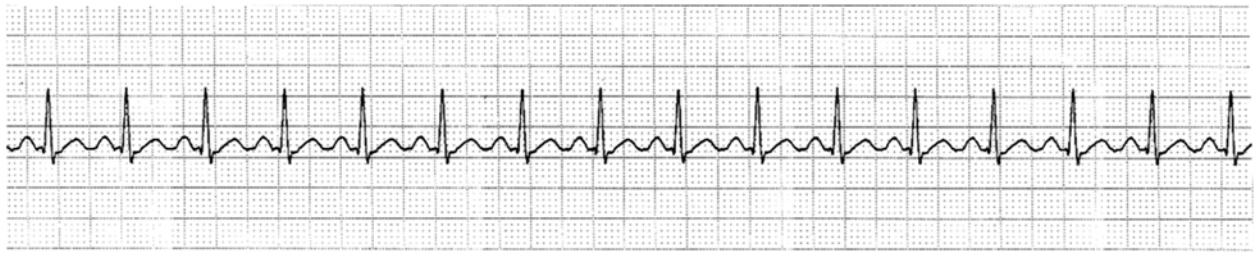Step 7: Rhythm

Remember the pathway of the circuit: SA Node to the AV node to the Bundle of His to the Purkinje fibers? Well this sequence is the normal sequence and it repeats itself again and again. Rhythms that occur from this sequence are called *SINUS* rhythms, meaning they all start in the SA node and follow the normal sequence.

So, usually we have "normal sinus rhythm".

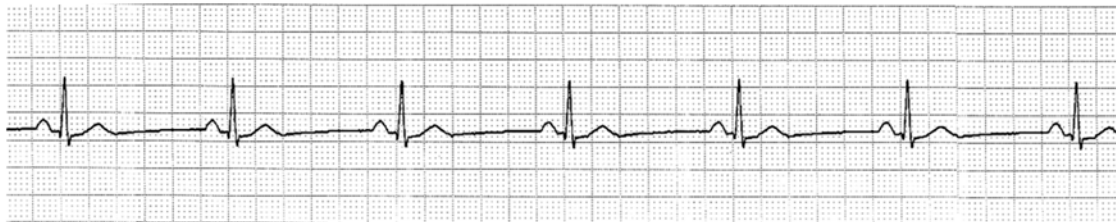

We can have a heart in a "sinus tachycardia", which means that the circuit sequence is normal, but it is cycling faster than 100 beats per minute. Therefore, our EKG will look normal, but just faster:



Notice that all the waves appear normal, there are regular P waves preceding each QRS complex and each wave is followed by a T.

We can also have a “sinus bradycardia”:



The same holds true for this strip: the waves all appear normal. There are regular P waves preceding each QRS and there is a T wave that follows the QRS. It is just going at a slower rate than normal.

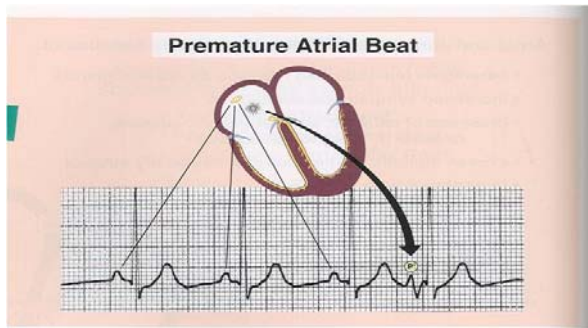
Step 8: Premature beats

We all have heard patients complain of an “extra beat” or a “skipped beat”. Often what is happening is a premature beat. This is where an excitable cell or area of the heart fires that is not along our regular pathway (SA node—AV node—Bundle of His—Purkinje fibers). We call this an “*ectopic foci*”. The word “ectopic” means in an unusual location, or not where it should be. “foci” is a plural of the word “focus” meaning a focal collection of excitable cells.

So, a premature beat is when an irritable focus spontaneously fires a single stimulus.

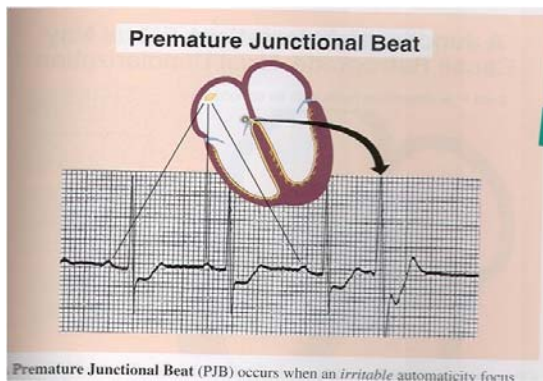
This can happen in any area of the heart. When it happens in the atria, the beat that results is called a premature atrial beat. When it happens at the junction of the atria and the ventricles, it is called a premature junctional beat. When it happens in the ventricles, it is called a premature ventricular beat.

So, what does a premature atrial beat look like on an EKG?



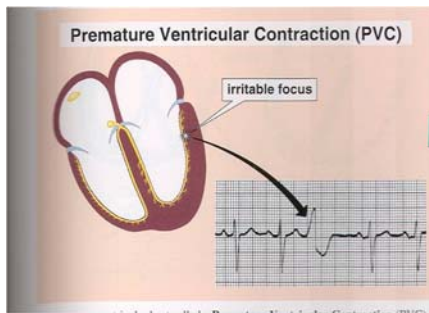
Notice that the first 3 P waves in this tracing are “normal”. They are originating from our SA node and therefore we see a normal QRS and T wave. Suddenly, the ectopic focus or an extra area in the atria (not the SA node) fires. This results in an abnormal looking P wave (represented by the P with the circle around it). In this example, this abnormal P wave conducted down to the AV node (who couldn’t differentiate it from the regular impulses) and our regular AV node was stimulated, propagating a normal looking QRS complex. This PAC (premature atrial contraction) occurred sooner than it should have and it looks abnormal.

Premature beats can occur at the AV junction as well. These are called PJC’s or premature junctional contractions. They look like this:



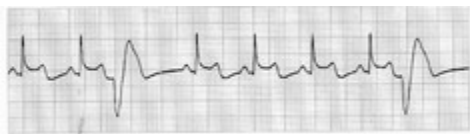
Again, in our example, the first three beats are normal. They arise from the SA node and travel through the normal circuitry. However, suddenly the AV node fires. This produces a QRS that doesn’t have a P in front of it and may look wider and more bizarre. Why does it look wider? It may not propagate down the Purkinje fibers simultaneously and the lag time will make the wave look wider, not slim and skinny.

If a beat originates in the ventricles, it is called a PVC or premature ventricular contraction. It looks like this on an EKG:

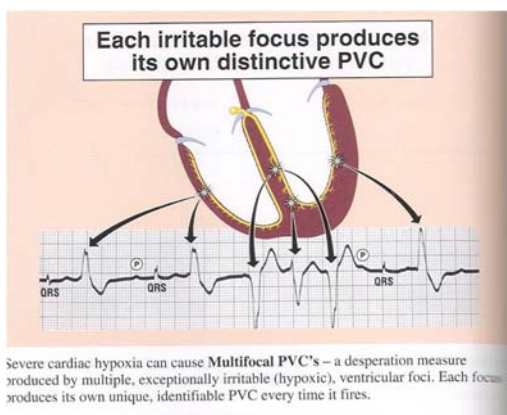


The origin is an irritable focus in the ventricles. It results in a wide, bizarre looking QRS that is all stretched out. Again, the stretched out appearance results from the fact that the wave is not traveling along the right and left Purkinje fibers simultaneously. In this example, first the left side fires, and then the right side fires.

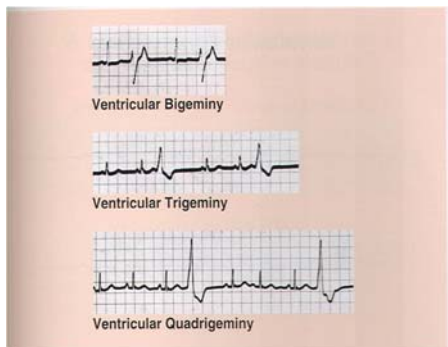
PVC's are fairly common when we look at EKG's. It is especially important to note the shape. PVC's that all look the same are usually coming from 1 ectopic focus. These are called *Unifocal PVC's*.



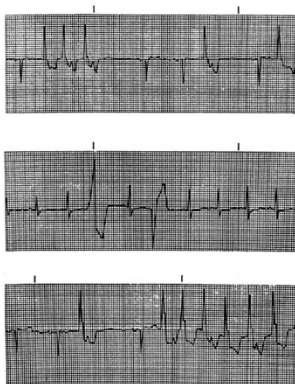
If there are multiple PVC's but they all look different, then they are originating from different or multiple ectopic foci. These are called *Multifocal PVC's*. This is a dangerous condition and is often caused by hypoxia (not enough oxygen).



PVC's can sometimes occur with regularity. When they occur at every other beat, the rhythm is called bigeminy. When the PVC's occur every 3rd beat, the rhythm is called trigeminy. When the PVC's occur at every 4th beat, the rhythm is called quadrigeminy.

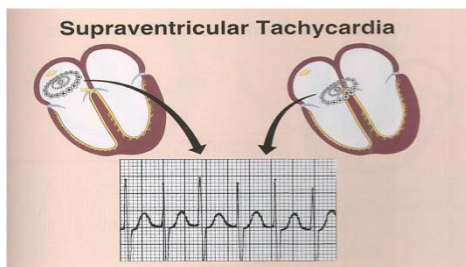


More ominously, the PVC's can start to occur in "runs" where they occur one right after another. This will look like this:



From here, the rhythm can rapidly degrade into Ventricular Tachycardia. This looks like a string of PVC's all run together. This is a very dangerous, potential fatal rhythm. Because the heart is not pumping in a coordinated fashion, the cardiac output (amount of blood pumping out of the heart) is dangerously low, if not non-existent. This has to be treated immediately.

The same thing can happen, but to an ectopic focus above the ventricles. This is called Supraventricular (above the ventricles) Tachycardia, or abbreviated SVT.



The most dangerous rhythm is *Ventricular Fibrillation*. This is the most common rhythm preceding a cardiac arrest in an adult patient. During this rhythm, there are multiple ectopic foci discharging all at once. The nice, coordinated pumping action of the heart is lost and the heart simply looks like a “bag of worms”. The chambers of the heart are simply twitching. The resulting rhythm is chaotic and erratic and tracing looks like a squiggly line.

